

6-1-2018

## EFFECT OF IMIDOCARB DIPROPIONATE ON FOETAL DEVELOPMENT IN RATS

Magdy S. Amer

Gehan N. Gad

*Animal Health Research Institute, Zagazig Pharmacology Department, Faculty of Veterinary Medicine, Mansoura University, Egypt*

Reham A. El-Shafei

Rasha A. Eltaysh

*See next page for additional authors*

Follow this and additional works at: <https://mvmj.researchcommons.org/home>

---

### How to Cite This Article

Amer, Magdy S.; Gad, Gehan N.; El-Shafei, Reham A.; Eltaysh, Rasha A.; and Abdel-Moaty, Fayza M. (2018) "EFFECT OF IMIDOCARB DIPROPIONATE ON FOETAL DEVELOPMENT IN RATS," *Mansoura Veterinary Medical Journal*: Vol. 19: Iss. 1, Article 1.

DOI: <https://doi.org/10.21608/mvmj.2018.117778>

This Original Article is brought to you for free and open access by Mansoura Veterinary Medical Journal. It has been accepted for inclusion in Mansoura Veterinary Medical Journal by an authorized editor of Mansoura Veterinary Medical Journal.

---

## EFFECT OF IMIDOCARB DIPROPIONATE ON FOETAL DEVELOPMENT IN RATS

### Authors

Magdy S. Amer, Gehan N. Gad, Reham A. El-Shafei, Rasha A. Eltaysh, and Fayza M. Abdel-Moaty

---

## Mansoura Veterinary Medical Journal

---

### EFFECT OF IMIDOCARB DIPROPIONATE ON FOETAL DEVELOPMENT IN RATS

Magdy S. Amer, \*Gehan N. Gad, Reham A. El-Shafei,  
Rasha A. Eltaysh and Fayza M. Abdel-Moaty

*\*Animal Health Research Institute, Zagazig  
Pharmacology Department, Faculty of Veterinary Medicine, Mansoura University, Egypt*

---

#### ABSTRACT

*Imidocarb is widely used in veterinary field as an antiprotozoal agent for the treatment of Babesiosis and Anaplasmosis. From this view, The toxicity of imidocarb was tested in female rat and their foeti. The study was applied on forty female mature rats which divided into four groups, 1st and 2nd groups were kept as control (injected normal saline intramuscularly on 6th and 10th day of pregnancy respectively), while the third group was injected by imidocarb (0.4 mg/kg b.wt.) on the 6th day of pregnancy, while the fourth group was injected with the therapeutic dose of imidocarb (.4 mg/kg b.wt) on the 10th day of pregnancy. Teratological and biochemical parameters alterations were estimated in this study. The results showed that the therapeutic dose of imidocarb on 6th day induced decrease in foetal body weight, increase the percent of absorbed foeti, decrease live foeti, and showed abnormalities in kidney (narrowing in renal pelvis) and heart (thickening in the ventricular wall). The results showed also absence and or incomplete ossification of cranium, xiphistrenebrae and caudal vertebrae. Histopathological examination revealed partial destruction of hepatic parenchyma in liver of dams, while massive peri-glomerular mononuclear cells infiltration in renal cortex in kidney of dams. Biochemical analysis evoked a significant increase in serum ALT and AST, Urea and creatinine, however it induce a significant decrease in serum total protein. So, we must increase the attention paid to the usage of imidocarb in pregnant animals.*

*Key words: Imidocarb / Genotoxicity / Teratogenicity / Antibabesial drugs.*

---

#### INTRODUCTION

In recent years, there has been a widespread and increasing concern about drugs, as well as environmental chemicals which may have a potential hazard to human beings or animals by inducing developmental malformations. The exposure to the teratogenic agents during prenatal development induce disruption regardless of the developmental stage or site of action. The structural alterations induced by teratogenic exposures occur during the embryonic period (Gilbert, 2003).

Many therapeutic agents that used in veterinary field for the control or treatment of many diseases evoked teratogenic effect in pregnant females (Aida El- Makawy et al, 2006).

Imidocarb is a carbanilide derivative with antiprotozoal activity. It is usually administered either as dipropionate salt or dihydrochloride salt. It has been approved since 1970's for the control and treatment of Babesiosis (in cattle and sheep) and Anaplasmosis in cattle (Lehner et al., 2011). Since many years, imidocarb still used for the cure of different protozoal infestation in different animals as cattle, sheep, horses and dogs (Mosqueda et al., 2012).

---

Imidocarb acts by binding to the nucleic acid of the DNA of the parasite, leading to denaturing and uncoiling of the DNA helix, with dilation of the nuclear cisternae, karyorrhexis, cytoplasmic vacuolation, inhibition of food vacuoles and ribosomal diminution (Nott et al., 1990).

The purpose of the present study was to evaluate the effect of Imidocarb dipropionate on developing rat foeti through morphological, visceral, skeletal and histopathologica examinations, also to investigate its effect on dams through estimation of some biochemical parameters in serum of mothers and evaluate histopathological changes in their liver, kidney and placenta.

## MATERIALS AND METHODS

### 1. Drug

Imidocarb dipropionate:- Imizol 12% (Schering-Plough- Co. USA). It is 12% solution for injection, which each imidocarb 85mg/ml equivalent to imidocarb dipropionate 121.15 mg/ml. The recommended therapeutic dose for prevention against babesiosis in dogs 6 mg Imidocarb per 1 kg b.w. that 0.5 ml per 10 kg body weight administrated once intramuscularly (Torbica, G. et al., 2013).

According to Paget and Barnes (1964) the dog dose was converted to rat dose (4.32 mg/200 gm b.wt = 0.036 ml) .

### 2. Experimental design:

The effects of imidocarb on foetal development were investigated on forty mature female albino rats, using twenty mature male albino rats for mating. Animals were kept under hygienic conditions housed in metal cages, fed on a balanced ration and watered ad-

libidum. They were accommodated to the laboratory conditions for two weeks before experimentation.

Daily vaginal smears were examined and the female proved to be in oestrus was paired with a male in a separate cage. In the following morning a vaginal smear was taken to verify the first day of gestation. Presence of sperms in the obtained vaginal smear indicates zero day of gestation (Barcellona et al., 1977). Pregnancy was confirmed by microscopic examination of vaginal smears, presence of permanent dioestrus indicated pregnancy. Body weight was recorded and prominent increases were observed chiefly after 10 days from the expected day of pregnancy. The pregnant rats were divided into four equal groups each of ten.

**Group I:** received normal saline once intramuscularly, on the 6<sup>th</sup> day of gestation as a control group.

**Group II:** received normal saline once intramuscularly, on the 10<sup>th</sup> day of pregnancy as a control group.

**Group III:** received therapeutic dose of imidocarb (4.32 mg/200 gm b.wt ) once intramuscularly, on the 6<sup>th</sup> day of pregnancy .

**Group IV:** received therapeutic dose of imidocarb (4.32 mg/200 gm b.wt ) once intramuscularly on the 10<sup>th</sup> day of pregnancy .

### 3. Effects on developing foeti (Teratological examination):

Drugs were injected on the 6<sup>th</sup> day of gestation period during which the organs are more sensitive to the effect of the toxic substances (Snell, 1982). The possible effects of them on developing foeti were evaluated by morphological, visceral and skeletal examination.

On day 20<sup>th</sup> of gestation period, all pregnant females from each group were sacrificed, the uterine horns were opened and The number of implantation and resorption sites were counted as described by **Kopf and Salewski, (1964)**.

The number of live and dead foeti, foetal body weight and foetal crown-rump length were recorded. The foeti were examined for any gross external malformations. Pre and post-implantation deaths were calculated according to **Hayes (1988)**. Foeti preserved in Bouin's fixative were rinsed with cold water and examined grossly. Stained skeletons with alizarin red stain were examined by a hand lens for any abnormalities in shape or size or absence of bones.

#### 4. Effects on biochemical parameters in dams serum :

**I- Determination of Liver function test (ALT and AST, TP, Albumin and Globulin):-** The concentration of Alanine aminotransferase (ALT) and Aspartate aminotransferase (AST) in serum were calculated colorimetrically according to **(Young,1995)**. Total protein was measured following the description of **Burtis (1999)**.

Albumin was measured in this study by using the bromocresol green method **(Stoskopf , 1993)**. Globulin concentrations are calculated by subtracting albumin concentrations from total protein concentrations **(Russell and Roussel, 2007)**.

#### **B- Determination of Kidney function test (Urea and Creatinine):-**

Urea level was estimated according to **(Burtis et al., 1999)**. Serum Creatinine level was determined calorimetrically according to the method of **Tiez et al (1995)**.

#### 5. Histopathological examination:-

Specimens of the liver, kidney, placenta of the mothers and liver, kidney of their foeti were prepared for histopathological examination **(Lillie and Fulman, 1976)**.

#### 6. Statistical analysis:

The data was analyzed by using computerized SPSS program version 16. Results are presented as mean±SE . The data were analyzed by one way ANOVA following by Duncan's test  $p \leq .05$  were considered significant according to **Tamh and Dunlop(2000)**.

## RESULTS

### 1-Effects on developing foeti :

The results recorded in Table (1) and illustrated in Figures (1-2 ) showed the effect of tested drugs on the developing foeti of pregnant dams (resorption sites, the numbers of implantation sites, resorbed, dead and viable foeti ) after their administration ( at 6<sup>th</sup> and 10<sup>th</sup> days of pregnancy) .

At 6<sup>th</sup> day of pregnancy; imidocarb evoked a significant decrease in the mean values of viable foeti , but it exposed a non significant alteration in the mean value of dead foeti and pre-implantation death and also revealed a significant increase in foetal resorption rate and post implantation death in compared with the control group.

At the 10<sup>th</sup> day of pregnancy : imidocarb evoked an insignificant change in the mean values of viable foeti, dead foeti, pre-implantation and post- implantation death, but it revealed a significant increase in foetal resorption rate in compared with the control group.

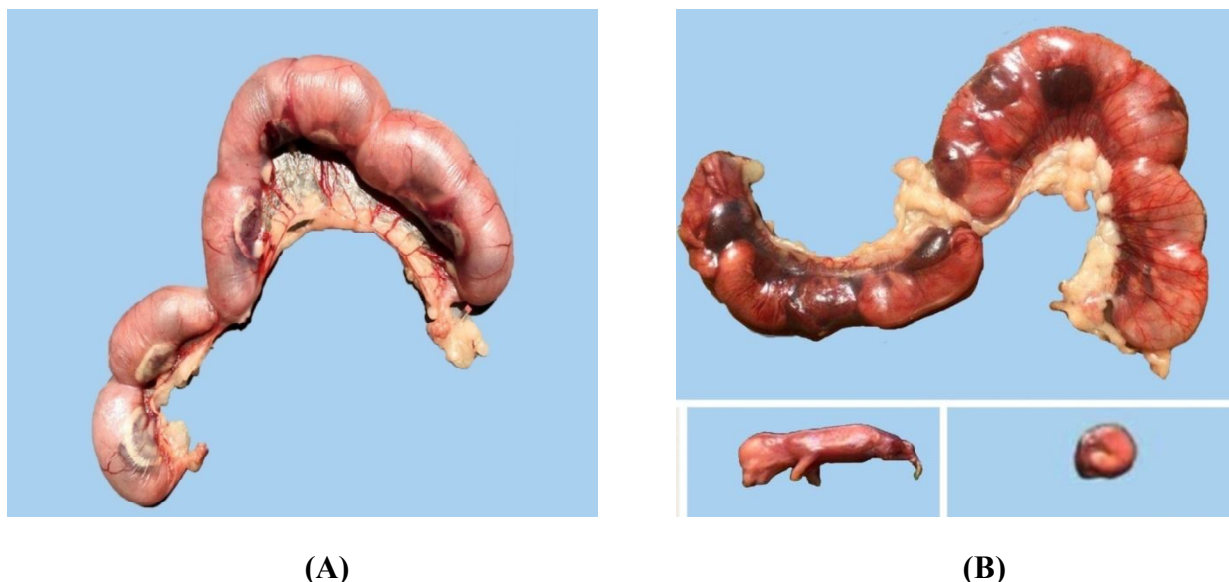
The possible effects of therapeutic dose of imidocarb on the 6<sup>th</sup> and 10<sup>th</sup> day of pregnancy on developing foeti were evaluated by morphological, visceral, skeletal, and histopathological examination:-

### 1- Morphological examination :

At the 6<sup>th</sup> day of pregnancy imidocarb induced a significant decrease in both mean

values of foetal body weight and the foetal crown-rump length of obtained foeti compared with the control.

At the 10<sup>th</sup> day of pregnancy imidocarb induced a significant decrease in both mean values of foetal body weight and the foetal crown-rump length of obtained foeti compared with the control.



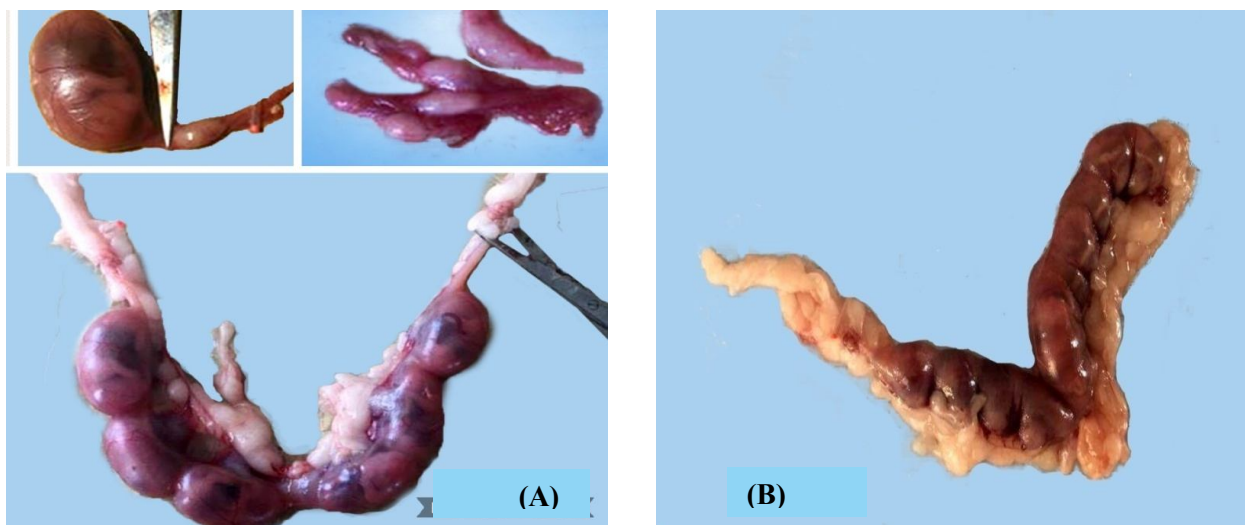
**Fig. (1) :** (A) Uterus of a pregnant rat (control) , reflected normal size of and complete number of the foeti, (B) Uterus of pregnant rat dam injected IM with Imidocarb (4.32 mg/200 gm b.wt ) on the 6<sup>th</sup> day of pregnancy shows foetal death and intrauterine hemorrhage.

Table.(1): Morphological changes and mortality rate in foeti from dam rats intramuscularly administered therapeutic dose of imidocarb (4.32 mg/200 gm b.wt) (Mean ± S.E) n=10.

Group	No.of. corpa lutea	No of implantation sites	Viable foeti		Dead foeti		Resorbes foeti		Foetl body weight (gm)	Foetal body length (cm)	Death	
			Mean ± S.E	%	Mean ± S.E	%	Mean ± S.E	%			Pre implantation	Post implantation
G1	8.4±0.24 <sup>a</sup>	8.0±0.32 <sup>a</sup>	7.4±0.51 <sup>a</sup>	92.1±3.2 <sup>a</sup>	0.2±.002 <sup>a</sup>	2.5±0.2 <sup>a</sup>	0.4±0.1 <sup>c</sup>	5.36±0.6 <sup>c</sup>	4.15±0.1 <sup>a</sup>	4.3±0.1 <sup>a</sup>	0.04±0.02 <sup>a</sup>	0.06±0.03 <sup>b</sup>
G2	8.0±0.32 <sup>a</sup>	8.0±0.31 <sup>a</sup>	7.8±0.37 <sup>a</sup>	97.5±2.5 <sup>a</sup>	0.2±0.02 <sup>a</sup>	2.5±0.2 <sup>a</sup>	0.0 <sup>c</sup>	0.0 <sup>d</sup>	4.48±0.14 <sup>a</sup>	4.2±0.1 <sup>a</sup>	0.0 <sup>a</sup>	0.03±0.01 <sup>b</sup>
G3	8.0±0.32 <sup>a</sup>	7.4±0.4 <sup>a</sup>	4.6±0.32 <sup>c</sup>	61.91±6.5 <sup>c</sup>	0.2±0.02 <sup>a</sup>	2.5±0.2 <sup>a</sup>	2.6±0.4 <sup>a</sup>	35.59±5.0 <sup>a</sup>	1.92±0.12 <sup>b</sup>	2.5±0.1 <sup>b</sup>	0.07±0.03 <sup>a</sup>	0.32±0.1 <sup>a</sup>
G5	8.2±0.37 <sup>a</sup>	8.2±0.37 <sup>a</sup>	6.2±0.2 <sup>b</sup>	76.03±3.1 <sup>b</sup>	0.4±0.12 <sup>a</sup>	4.72±0.32 <sup>a</sup>	1.6±0.1 <sup>b</sup>	19.25±2.4 <sup>b</sup>	2.1±0.1 <sup>b</sup>	2.5±0.14 <sup>b</sup>	0.0 <sup>a</sup>	0.22±0.01 <sup>ab</sup>

Different letters in the same column means significant difference at (P ≤ .05)

- G1: Control group injected with normal saline I/M once on the 6<sup>th</sup> day.
- G2: Control group injected with normal saline I/M once on the 10<sup>th</sup> day.
- G3: Dams administrated therapeutic dose of imidocarb once I/M on the 6<sup>th</sup> day.
- G5: Dams administrated therapeutic dose of imidocarb once I/M on the 10<sup>th</sup> day.



**Fig.(2):** Uterus of pregnant rat dam injected IM with Imidocarb (4.32 mg/200 gm b.wt ) at 6th day of pregnancy shows (A) foetal resorption, (B) foetal resorption and reduced foetal weight.

**2-Visceral examination:-**

Table (2). show the detailed examination of previous visceral abnormalities that revealed hemorrhage in the brain, thickening of the ventricular wall of the heart and a narrowing of the pelvis (Figures 3) .

At the 6<sup>th</sup> day of pregnancy , Imidocarb evoked no foetal malformations in palate

nor brain , but showed abnormalities in kidney and heart with a percent of (72.7%)and (63.6%) respectively. At the 10<sup>th</sup> day of pregnancy the obtained results Imidocarb not record foetal malformations in palate nor brain , but induced abnormalities in kidney and heart with a percent of 46.6% and 46.6% respectively.

**Table (2):** Visceral malformations in foeti from dam rats intramuscularly administered therapeutic dose of imidocarb (4.32 mg/200 gm b.wt ) on the 6<sup>th</sup> and 10<sup>th</sup> day of pregnancy.

Group	No of examined foeti	Malformations							
		Palate		Brain		Kidney		Heart	
		No	%	NO	%	NO	%	NO	%
G1	18	-	-	0	0	0	0	0	0
G2	19	-	-	0	0	0	0	0	0
G3	11	-	-	0	0	8	72.7	9	63.6
G5	15	-	-	0	0	7	46.6	7	46.6


**G1:** Control group injected with normal saline I/M once on the 6<sup>th</sup> day.

**G2 :** Control group injected with normal saline I/M once on the 10<sup>th</sup> day.

**G3 :** Dams administrated therapeutic dose of imidocarb once I/M on the 6<sup>th</sup> day .

**G5 :** Dams administrated therapeutic dose of imidocarb once I/M on the 10<sup>th</sup> day.





**Fig.(3):** Cross section in the head, heart ventricles and kidney of the rat foeti from dams,(a) from the control group, (b) from a dams given the therapeutic dose of imidocarb (4.32 mg/200 gm b.wt ) injected IM on the 6<sup>th</sup> day of gestation period show hemorrhage in the brain, thickening of the ventricular wall of the heart and Narrowing of the renal pelvis compared with control (a)

### 3- Skeletal examination :-

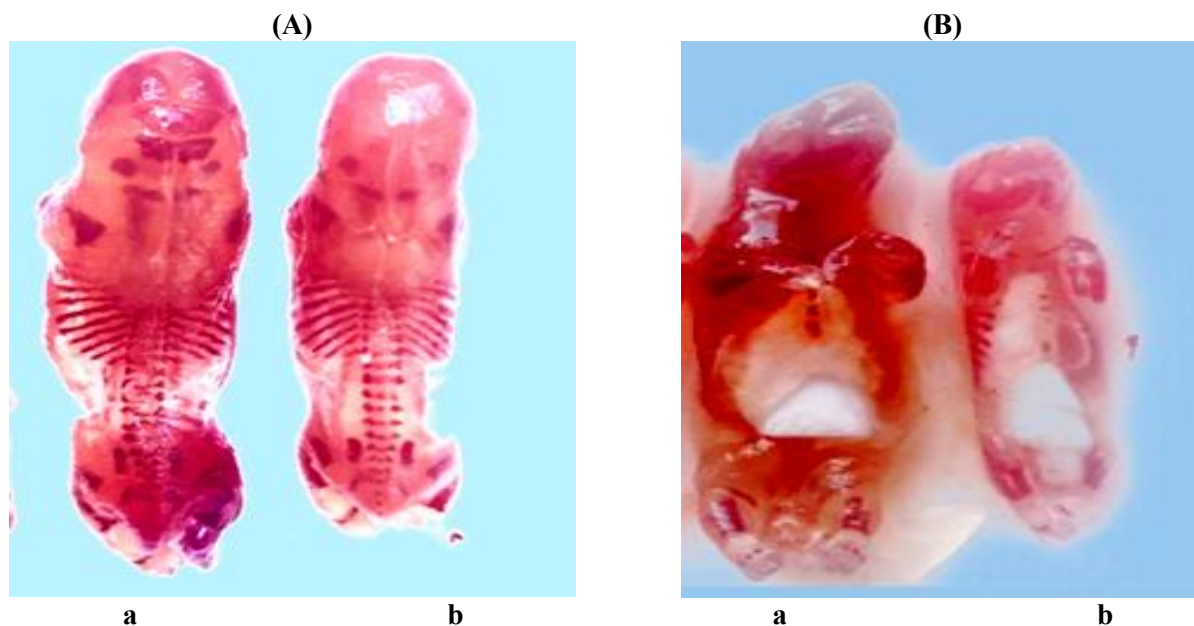
The obtained data were recorded in Table (3) and illustrated in **Figures (4-5)**. Under the influence of the drugs administered with therapeutic doses to pregnant rats during 6<sup>th</sup>

and 10<sup>th</sup> day of pregnancy , the results showed , absence and or incomplete of ossification of cranium ,xiphistrenebrae ,strenebrae, sacral, hind limb and caudal vertebrae in foeti of treated pregnant dams.

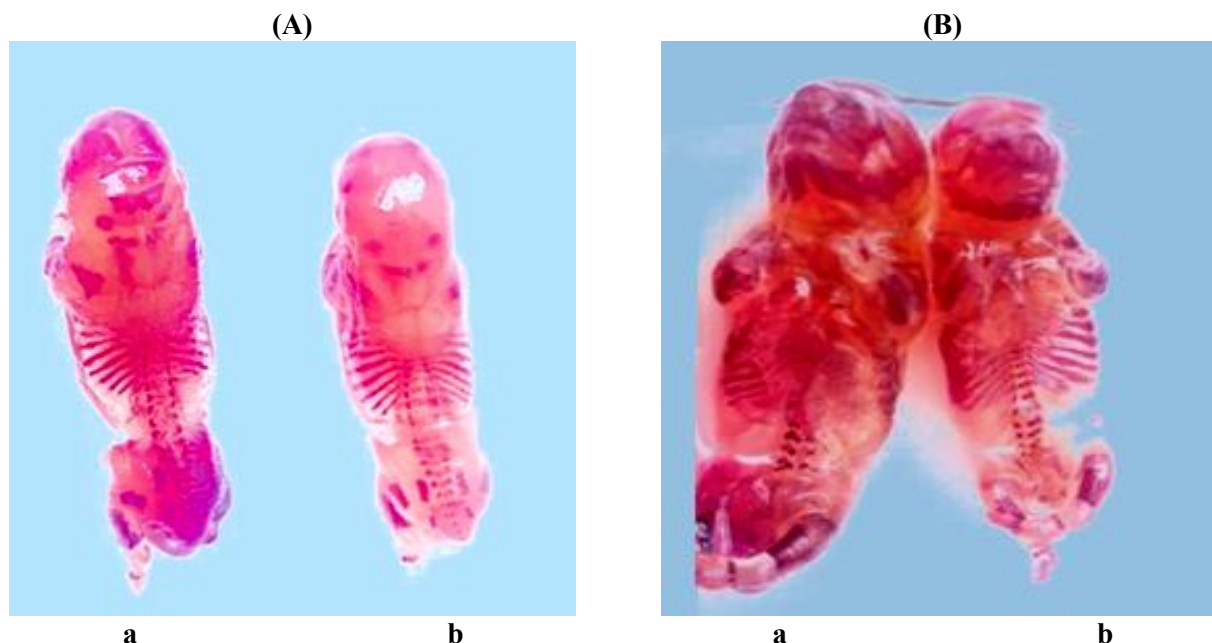
**Table.(3)** : Skeletal malformations in foeti from dam rats intramuscularly administered therapeutic dose of imidocarb (4.32 mg/200 gm b.wt) on the 6<sup>th</sup> and 10<sup>th</sup> day of pregnancy.

group	No. of examined foeti	Incomplete ossification		Large fontella		Sternbrae and xiphistrenebrae cartilage				Incomplete and Abscence					
		No.	%	NO	%	Incomplete		Abscence		Sacral vertbrae		Lumbar vertebrae		Caudal vertebrae	
						No	%	No	%	No	%	No	%		
														No	%
G1	18	0.0	0.0	0.0	0.0	0.0	0.0	0.0	0.0	0.0	0.0	0.0	0.0	0.0	0.0
G2	19	0.0	0.0	0.0	0.0	0.0	0.0	0.0	0.0	0.0	0.0	0.0	0.0	0.0	0.0
G3	11	1	9	0.0	0.0	3	27.3	3	27.3	1	9.1	0.0	0.0	2	18.2
G5	15	6	40	3	20	11	73.3	8	53.3	4	26.6	2	13.3	6	40

**G1**: Control group injected with normal saline I/M once on the 6<sup>th</sup> day.  
**G2** : Control group injected with normal saline I/M once on the 10<sup>th</sup> day.  
**G3** : Dams administrated therapeutic dose of imidocarb once I/M on the 6<sup>th</sup> day .  
**G5** : Dams administrated therapeutic dose of imidocarb once I/M on the 10<sup>th</sup> day.



**Fig. (4):** (A) A photograph showing ventrodorsal view of skeletons of rat foeti (a) from control dams (b) from dams given therapeutic dose of imidocarb (4.32 mg/200 gm b.wt) IM on the 6<sup>th</sup> day shows hypoplasia of xiphoid cartilage, absence of 2<sup>nd</sup> sternbrae, hypoplasia of 1,3,4,5<sup>th</sup> sternbrae (B) A ventrodorsal view of skeletons of rat foeti (b) dams given therapeutic dose of imidocarb showing hypoplasia of xiphoid cartilage, absence of 2<sup>nd</sup> sternbrae, hypoplasia of 1,3,4,5<sup>th</sup> sternbrae.



**Fig.(5) :** (A) A photograph showing a dorso-ventral view ) of skeletons of rat foeti (a) from control dams (b). from dams given therapeutic dose of imidocarb (4.32 mg/200 gm b.wt ) IM on the 10<sup>th</sup> day of pregnancy showing incomplete ossification of cranium (B) a ventrodorsal view of skeletons of rat foeti (b). from dams given therapeutic dose of imidocarb IM on the 10<sup>th</sup> day of pregnancy showing hypoplasia of 1<sup>st</sup>, 2<sup>nd</sup> 3<sup>rd</sup> and absence of 4,5<sup>th</sup> sternbrae and absence of xiphoid cartilage

#### 4-Histopathological finding in dams samples:-

##### 1. Liver:-

At the 6<sup>th</sup> day of pregnancy therapeutic dose of imidocarb (4.32 mg/200 gm b.wt ) evoked severe congestion of hepatic BL.V , perivascular edema , partial destruction of hepatic parenchyma, while at the 10<sup>th</sup> day of pregnancy therapeutic dose of imidocarb (4.32 mg/200 gm b.wt ). induced focal mononuclear cell infiltration in hepatic parynchema (Figure 6-7) .

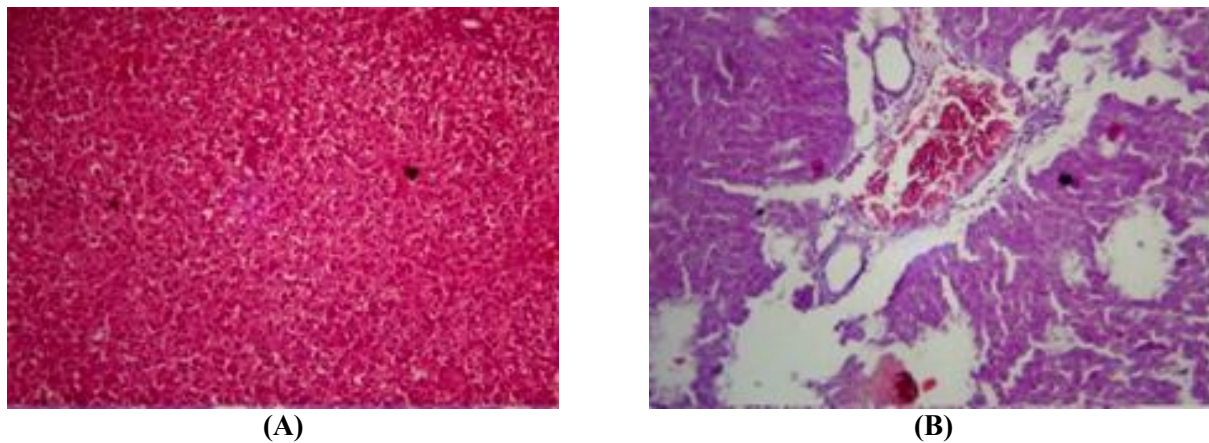
##### 2. Kidney:-

At the 6<sup>th</sup> day of pregnancy therapeutic dose of imidocarb (4.32 mg/200 gm b.wt).

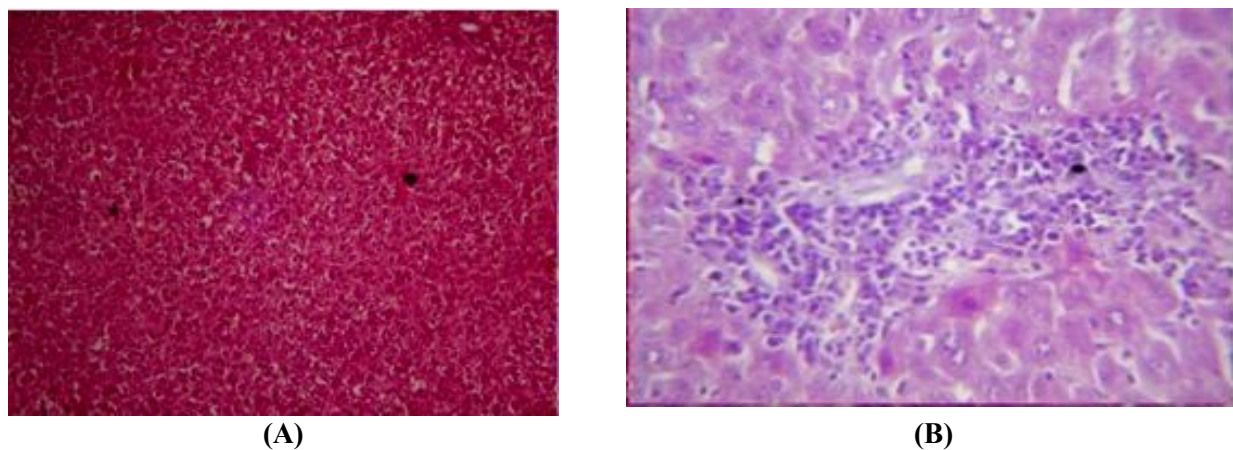
revealed severe congestion of renal Blood vessels , thickening of its wall in addition to degeneration of some renal tubules , while at the 10<sup>th</sup> day of pregnancy the given imidocarb at (4.32 mg/200 gm b.wt ) evoked massive periglomerular mononuclear cells infiltration in renal cortex (Figures, 8-9).

##### 3.Placenta:-

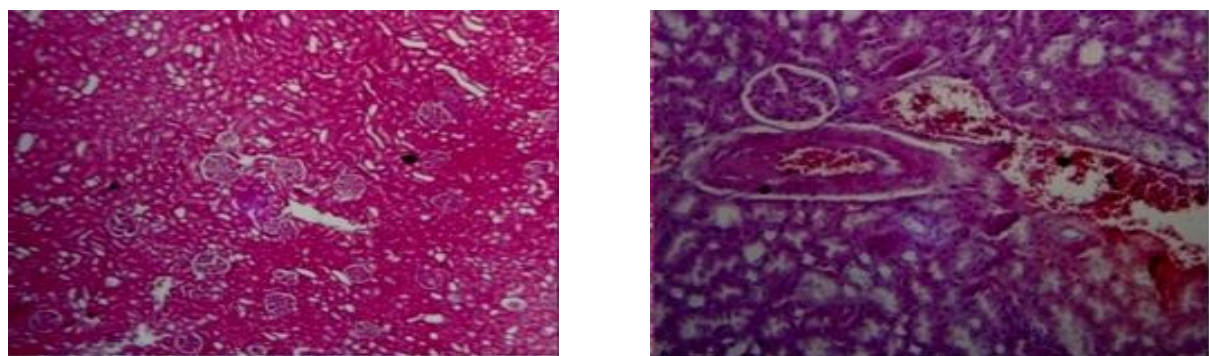
Placental examination of dam rats received therapeutic dose of imidocarb (4.32 mg/200 gm b.wt) displayed decrease number of trophoblastic cells and sponio trophoblast atrophy in uterine gland , (Figure,10).



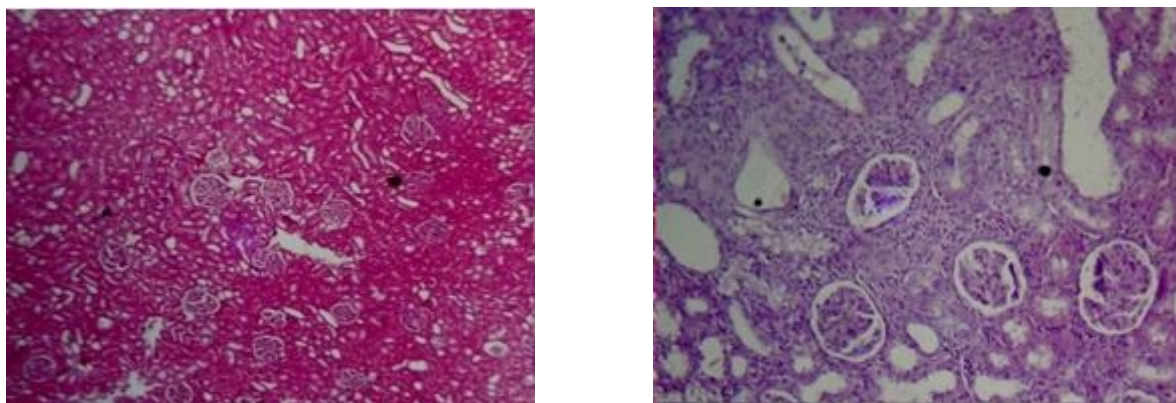
**Fig. (6) :** Figure of liver dam rat at different stages of pregnancy where (A) : normal structure of control dam liver at 6<sup>th</sup> day of pregnancy (B): liver dam rat injected with imidocarb at 6<sup>th</sup> day of pregnancy shows severe congestion of hepatic BL.V , perivascular edema , partial destruction of hepatic parenchyma.



**Fig. (7) :** Figure of liver dam rat at different stages of pregnancy where (A) : normal structure of control dam liver at 10<sup>th</sup> day of pregnancy (B) liver dam rat injected with imidocarb at 10<sup>th</sup> day of pregnancy shows focal mononuclear cell infiltration in hepatic parenchyma

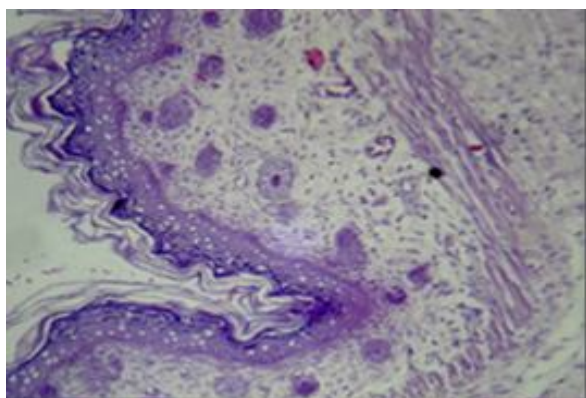


**Fig . (8) :** Figure of kidney dam sections of dams rat during pregnancy where (A) shows normal structure of kidney of control group show normal renal parenchyma and cellular details , (B) kidney section of rat dam injected IM with imidocarb on 6<sup>th</sup> day of pregnancy shows severe congestion of renal Blood vessels & thickening of it's wall in addition to degeneration of some renal tubule.

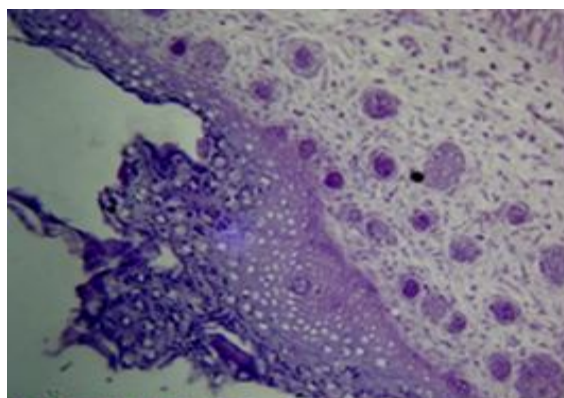


**Fig . (9) :** Figure of kidney dam sections of dams rat during pregnancy where (A) shows normal structure of kidney of control group show normal renal parenchyma and cellular details (B) kidney rat dam injected IM with imidocarb at 10<sup>th</sup> day of pregnancy shows massive periglomerular mononuclear cells infiltration in renal cortex ( H&E 400).

(A)



(B)



**Fig.(10):** Figure of placenta cross sections where (A) cross section of placenta of dam rat of control group shows normal layers and cellular contents, (B) cross section of placenta rat IM injected with imidocarb shows decrease number of trophoblastic cells and spongiotrophoblast atrophy in uterine gland.

## II- Effects of imidocarb on biochemical parameters of treated dams

The effect of the tested drugs on some serum biochemical parameters of treated groups (ALT-AST-Total protein-Albumin-Urea-Creatinine) compared with the control group as shown in **Table (3)**.

At the 6<sup>th</sup> and 10<sup>th</sup> day of pregnancy both treated groups showed a significant increase with imidocarb in serum transferases levels ALT and AST compared with control group.

Imidocarb evoked a non significant change in serum total protein of treated group at 6<sup>th</sup> day of pregnancy, while at 10<sup>th</sup> day of pregnancy the drug induced a significant decrease in serum total protein level compared with control group at 6<sup>th</sup> and 10<sup>th</sup> days of pregnancy.

At the 6<sup>th</sup> day of pregnancy , the treated group with imidocarb showed insignificant change while at the 10<sup>th</sup> day of pregnancy , the treated groups with reflected a significant decrease in serum albumin levels compared with control group. At the 6<sup>th</sup> and 10<sup>th</sup> day of

pregnancy a non significant increase in serum globulin levels in serum of treated groups with imidocarb in serum globulin level compared with control group.

The tested drug induced a significant increase in serum urea and creatinine level of

treated groups in comparison with the control group at 6<sup>th</sup> day of pregnancy and also at 10<sup>th</sup> day of pregnancy compared with the control group serum urea level compared with control group.

**Table (3) :** Effect of IM administration of therapeutic dose of Imidocarb (4.32 mg/200 gm b.wt ) on the 6<sup>th</sup> and 10<sup>th</sup> day of pregnancy on biochemical parameters of treated group (Mean  $\pm$  SE) (n=10)

Group	ALT	AST	Urea	creatinine	Total Protein	Albumin	Globulin
G1	20.8 $\pm$ 0. <sup>b</sup>	68.17 $\pm$ 1.6 <sup>b</sup>	31.84 $\pm$ 0.6 <sup>b</sup>	0.62 $\pm$ 0.02 <sup>c</sup>	6.44 $\pm$ 0.1 <sup>a</sup>	4.42 $\pm$ 0.07 <sup>a</sup>	2.02 $\pm$ 0.1 <sup>b</sup>
G2	21.42 $\pm$ 0.8 <sup>b</sup>	68.9 $\pm$ 1.8 <sup>b</sup>	31.8 $\pm$ 0.58 <sup>b</sup>	0.72 $\pm$ 0.01 <sup>c</sup>	6.52 $\pm$ 0.1 <sup>a</sup>	4.44 $\pm$ 0.1 <sup>a</sup>	2.08 $\pm$ 0.1 <sup>b</sup>
G3	25.58 $\pm$ 0.59 <sup>a</sup>	86.5 $\pm$ 3.38 <sup>a</sup>	37.0 $\pm$ 0.5 <sup>a</sup>	3.78 $\pm$ 0.1 <sup>b</sup>	6.92 $\pm$ 0.13 <sup>a</sup>	4.11 $\pm$ 0.1 <sup>a</sup>	2.81 $\pm$ 0.1 <sup>a</sup>
G5	26.6 $\pm$ 0.59 <sup>a</sup>	86.5 $\pm$ 0.5 <sup>a</sup>	38.16 $\pm$ 0.3 <sup>a</sup>	5.83 $\pm$ 0.2 <sup>a</sup>	5.98 $\pm$ 0.26 <sup>a</sup>	3.92 $\pm$ 0.1 <sup>a</sup>	2.06 $\pm$ 0.1 <sup>b</sup>

G1: Control group injected with normal saline I/M once on the 6<sup>th</sup> day.

G2 : Control group injected with normal saline I/M once on the 10<sup>th</sup> day.

G3 : Dams administrated therapeutic dose of imidocarb once I/M on the 6<sup>th</sup> day .

G5 : Dams administrated therapeutic dose of imidocarb once I/M on the 10<sup>th</sup> day

## DISCUSSION

Parasitic infestations are common during pregnancy, and like anybody else, pregnant animal are susceptible to infections. Virtually most drugs cross the placenta and thus have the potential to affect the fetus adversely (**Dashe and Gilstrap, 1997**). Imidocarb has been used for more than 20 years for the cure of many protozoal infestation as Babesiosis and Anaplasmosis in different animals (**JECFA,1998**).

### K- Effects on developing foeti :

Regarding the effects of imidocarb on each of foetal resorption rate, pre-implantation and post-implantation death in treated groups at the 6th and 10th days of pregnancy , the results showed that imidocarb induced a significant increase in foetal resorption rate . and a non significant increase in post-implantation death.

Many authors supported the results occurred by imidocarb, **Hart (1973)** found that , imidocarb significantly increased the incidence of resorption in tested dams . Also **James (1977)** reported that imidocarb dipropionate increased the number of missing fetus of treated female rats.

The obtained data showed that imidocarb at the 6<sup>th</sup> and 10<sup>th</sup> days of pregnancy evoked a significant decrease in each of foetal mean value of body weight and foetal crown-rump length. These findings are in agreement with results previously recorded by many authors . **Tesh et al (1977)** . Similar result in female rats was obtained by **EMEA(2001)** who said that , imidocarb dipropionate significantly reduced the foetal body weight and length . Also **Valeri (2005)** reported that , imidocarb

penetrates the placental barrier and induced a decrease in weight of offspring .

Visceral examination of foeti obtained from dams administrated imidocarb at the 6<sup>th</sup> and 10<sup>th</sup> days of pregnancy showed that abnormalities in kidney (narrowing of the renal pelvis ) and heart (disclosing thickening of the ventricular wall of the heart) but no foetal malformations in palate .

Similar findings were observed with many authors. **Brown (1979)** stated that administration of imidocarb dipropionate significantly increased the mean of kidney weight in rats received the highest dose **Panghal (2002)** noticed hepatomegaly in livers of treated rats with imidocarb and kidneys were enlarged and congested with extensive hemorrhage in the cortex and medulla. **Valerie (2005)** found that imidocarb induced severe renal tubular necrosis in dogs. Also **O'Brien (2008)** reported that , imidocarb treatment affected the heart function , but is not a highly potent cardiotoxic agent. Similar results was observed by **Ekici and Isik (2011)** who said that , imidocarb may interfere with the heart function.

The obtained skeletons from foeti its' dam treated with imidocarb showed incomplete ossification, incomplete and absence of sternbrae and xiphistrenebrae cartilage , lumbar vertebrae while also showed incomplete and absence of sacral and caudal vertebrae.

**James (1977)** mentioned that administration of imidocarb dipropionate orally to pregnant rats increased the incidence of fetus with bifid sternbrae. In the same ground , **EMEA (2001)** reported that female rabbits given imidocarb from the day 6<sup>th</sup> to 18<sup>th</sup> of gestation increased the incidence of foetal delayed ossification. In the obtained liver samples from pregnant females imidocarb showed severe congestion of hepatic BL.V ,

perivascular edema , partial destruction of hepatic parenchyma , focal mononuclear cell infiltration in hepatic parynchema .

The obtained results were in aggrement with previously mentioned results of many authors. **Bushby (1970)**, **Reynolds et al (1977)**, and **Brown (1979)** mentioned that imidocarb caused many hepatic lesions as (cloudy swelling, focal haemorrhagic necrosis, fatty changes , vacuolation of hepatocyte, deposition of brown pigment in macrophages and related hepatocytes Also, **Abdullah et al (1984)** in addition to **Angela Pelzel-McCluskey and Josie Traub-Dargatz (2015)** reported that imidocarb has a dose-dependant hepatotoxicity with hepatocellular necrosis. Also **Miodrag Ristic(2018)** stated that imidocarb increase severity of hepatic lesions, mortality which occured within 6 days following the first injection because of acute periportal hepatic necrosis .

The treated rats' kidneys with imidocarb evoked severe congestion of renal blood vessels and thickening of its wall in addition to degeneration of some renal tubules, massive periglomerular mononuclear cells in renal cortex.

These findings are supported by **Panghal (2002)** whose recorded that imidocarb caused (pyknosis and karyorrhexis of the tubular epithelial nuclei ,tubulonephrosis and severe acute tubular necrosis of the proximal convoluted tubules) on 1st and 2nd days after administration. **Angela Pelzel-McCluskey and Josie Traub-Dargatz (2015)** reported that imidocarb has a dose dependant nephrotoxicosis with loss of cell membrane permeability and cell swelling resulted in acute renal cortical tubular necrosis. Also **Miodrag Ristic(2018)** stated that imidocarb increase severity of renal lesions mortality which occured within 6 days following the first

injection because of acute cortical tubular renal necrosis .

Placental sections revealed that imidocarb caused decrease in the number of trophoblastic cells and sponio trophoblast atrophy in uterine gland. **Lewis et al (1999)** mentioned that imidocarb cross placenta to be found in foetal blood at the same concentration of dam's blood .

## II- Effects of imidocarb on some biochemical parameters of treated dams

The mentioned results are supported with **(Ali et al.,1985)** who found that imidocarb (IM) on goats has a dose-related increases in aspartate aminotransferase activity. In matching with , **EKICI and ISIK (2011)** who elicited that 6 hours after a single subcutaneous injection of imidocarb in lambs lead to a significant increase in ALT, AST. **Dailymed (2017)** recorded that when imidocarb was administered S/C to dogs resulted in a slight increase in serum alanine aminotransferase (ALT) and (AST) indicative of mild liver injury. Also **Miodrag Ristic(2018)** stated that imidocarb increase level of serum aspartate ,aminotranseferase.

In the light of the study imidocarb at the 6<sup>th</sup> day of pregnancy reflected insignificant change in serum total protein and albumin while at the 10<sup>th</sup> day of pregnancy , it reflected a significant decrease in their levels. Also imidocarb caused a significant increase only at 6th day of pregnancy in serum globulin level while at 10<sup>th</sup> day reflected an insignificant change .

The obtained results were in aggrement with previously mentioned results of many authors **EKICI and ISIK (2011)** elicited that after 6h of a single subcutaneous injection of imidocarb in lambs lead to a non significant change in total protein, albumin and



myoglobin concentrations which remained constant .

At both the 6<sup>th</sup> and 10<sup>th</sup> days of pregnancy imidocarb reflected a significant increase in serum urea level and serum creatinine level. **Brown (1979)** stated that administration of imidocarb dipropionate on rats for 104 week increased alkaline phosphatase activity and blood urea nitrogen concentration. In addition to **(Ali et al.,1985)** who found that imidocarb (IM) on goats has a dose-related increases in creatinine and bilirubin concentrations , while **EKICI and ISIK (2011)** elicited that 6 hours after a single subcutaneous injection of imidocarb in lambs lead to a significant increase in creatinine.

#### REFERENCES

- Abdullah, A.S. ; Shekh Omar; A.R.; Baggot, J.D. and Zamri, M (1984):** Adverse effects of imidocarb (Imizol) in a dog. *Vet. Res. Commun.*8(1), 55-59.
- Aida EL makawy; Hasnaa A Radwan; Inas Ghaly and A Abd El-Raouf(2006):** Genotoxic, teratological and biochemical effects of anthelmintic drug oxfendazole Maximum Residue Limit (MRL) in male and female mice. *Reproduction Nutrition Development* ,46(2),139-56.
- Ali, B.H; T. Hassan; H.B. Suliman and A.B. Adelsalam(1985):** Some effects of imidocarb in goats. *Veterinary and Human Toxicology*, 27(6): 477-480.
- Angela Pelzel-McCluskey and Josie L. Traub-Dargatz (2015):** Robinson's Current Therapy in Equine Medicine, 480-483.
- Barcellona, P.S.; Fanell, O. and Campana, A. (1977):** Teratological studies of etoperidone in the rat and rabbit. *Toxicol.*,2:87-94
- Brander, G.C. and Pugh D.M. (1977):** *Veterinary Applied Pharmacology and Therapeutics* 3rd Ed. Bailliere Tindall, London.
- Brown, D. (1979):** A two year feeding study in the rat with compound 4A. Unpublished report No. XZIG 86-C1 from Hazleton Laboratories Europe Ltd, Harrogate, United Kingdom. Submitted to WHO by Mallinckrodt, Harefield, Uxbridge, Middlesex, United Kingdom.
- Burtis, Carl A., Ashwood and Edward R. (1999):** Tietz, Norbert *WTIETZ TEXTBOOK CLINICAL CHEMISTRY* , 3rd Ed, AACC. Philadelphia, WA Saunders.
- Bushby, S.R.M. (1970):** Prolonged toxicity examination of 4A65 di Hcl in the rat. Unpublished report No. HZIG 76-2 from Wellcome Research Laboratories, Berkhamsted, United Kingdom. Mallinckrodt, Harefield, Uxbridge, Middlesex, United Kingdom.
- Dailymed."**Imizol (Imidocarb Dipropionate) Injection, Solution [Merck Sharp & Dohme CORP .
- Dashe JS and Gilstrap LC (1997):** Antibiotic Use In Pregnancy. *Obstet Gynecol Clin North Am*,24(3),617-29.
- EKICI O.D. and ISIK N. (2011):** Investigation of the cardiotoxicity of imidocarb in lambs, *Revue Méd. Vét.*, 2011, 162, 1, 40-44.

- EMA/MRL. 2001.** The European Agency for the evaluation of Medicinal Products. Veterinary Medicines and Inspections. 785/01-FINAL, May, 2001.
- Gilbert SF(2003):** Developmental Biology, 7th Ed. Sinauer Associates, Sunderland, MA, 694–696.
- Hart, E.R. (1973):** 90-day feeding study in rats. Imidicarb dipropionate. Unpublished report No. XZIG 86-4 from Litton Bionetics, Inc., Bethesda, Maryland, USA. Submitted to WHO by Mallinckrodt, Harefield, Uxbridge, Middlesex, United Kingdom.
- Hart, E.R. (1973):** Teratology phase. Imidocarb dipropionate. Final report. Unpublished report No. XZIG 86-7 from Litton Bionetics, Inc., Bethesda, Maryland, USA. Submitted to WHO by Mallinckrodt.
- Hayes, A. W. (1988):** Principles and Methods of Toxicology 2<sup>nd</sup> Ed., pp. 320-359. Raven Press, New York.
- James, D.A. (1977):** Multigeneration reproduction study of (imidocarb dipropionate) in the rat. from Wellcome Research Laboratories, Beckenham, Kent, United Kingdom. Submitted to WHO by Mallinckrodt, Harefield, Uxbridge, Middlesex, United Kingdom.
- (JECFA) Joint FAO/WHO Expert Committee on Food Additives (1998):** WHO FOOD ADDITIVES SERIES 41 Prepared by The 50th meeting of the World Health Organization.
- Joint FAO/WHO Expert Committee on Food Additives.** Meeting Residues of Some Veterinary Drugs in Animals and Foods: Monographs Prepared fiftieth meeting of the joint FAO/who expert committee on food additives Rome ,17-26 february 1998
- KOCK, N. and KELLY, P. (1991):** Massive hepatic necrosis associated with accidental imidocarb dipropionate toxicosis in a dog. J. Comp. Pathol., 1991, 104, 113-116.
- Kopf, R. And Salewski, S.D. (1964):** Chemoteratogenesis. Arch. Expt. Pathol. Pharmacol., 274, 367.
- Lehner, A.F. ; Hitron, J. A. ; May, J. ; Hughes, C. ; Eisenberg, R. ; Schwint, N. ; Knowles, D.P. ; Timoney, P. and Tobin, T., (2011):** Evaluation of Mass Spectrometric Methods for Detection of the Anti-Protozoal Drug Imidocarb. Journal of Analytical Toxicology. 35 (4), 199–204.
- Lewis, B.D. ; Penzhorn, B. and Volkmann, D.H.(1999):** Could treatment of pregnant mares prevent abortions due to equine piroplasmiasis?. Journal of the South African Veterinary Association 70(2),90-1
- Lillie, R. D. and Fulman, H. M. (1976):** Histopathological technique and practical histopathology. The blauiston division, New York and London, Acad. Sci., 111: 789-792.
- Miodrag Ristic (2018):** Babesiosis of Domestic Animals and Man, CRC Press.
- Mosqueda, J. ; Olvera-Ramirez, A. ; Aguilar-Tipacamu, G. and Canto J.G.,(2012):** Current Medicinal Chemistry. Bentham Science Publishers, 19( 10), 1504-1518.

- Nott, S.E. ; O'Sullivan, W.J. ; Gero, A.M. and Bagnara, A.S. (1990):** Routine screening for potential babesiocides using cultures of *Babesia bovis*. Indian Journal of Parasitology, 20, 797–802.
- O'BRIEN P.J. (2008):** Cardiac troponin is the most effective translational safety biomarker for myocardial injury in cardiotoxicity. Toxicology, 245, 206-218.
- Paget, S. and Barnes, R. (1964):** Evaluation of drug activities, pharmacometrics, Eds. Laurence and Bachrach, Vol. 1., Academic Press, New York.
- Panghal R. S. ; Rana, R. D. And Vinod Kumar (2009):** Effects Of Imidocarb On Cholinesterase Activity And Grossly Observable Behaviour In Dogs Haryana Vet, 48,26-28.
- Reynolds, J. ; Clampitt, R.B. ; Piercy, D.W.T. ; James, J.A. and Skarpa, M. (1977):** Subacute 90 day oral toxicity of imidocarb dipropionate in the dog. Unpublished report No. HZIG 77-11 from Wellcome Research Laboratories, Berkhamsted and Beckenham, United Kingdom. Submitted to WHO by Mallinckrodt, Harefield, Uxbridge, Middlesex, United Kingdom.
- Russell, K.E. and Roussel, A.J.(2007):** Evaluation of the ruminant serum chemistry profile. Vet. Clin. Food. Anim.23,403–426.
- Stoskopf, M.K.(1993):** Clinical Pathology. In Fish Medicine. Stoskopf, M.K., Ed. Philadelphia, PA, USA.
- Tamhane, A. and Dunlop, D. (2000):** Statistic and Data Analysis from Elementry to Intermediate. Prentice Hall, Upper Saddle River, New Jersey.USA.
- Tesh, J.M. ; Ross, F.W. and Tesh, S.A (1977) :** Effects of oral administration upon pregnancy in the rabbit. Unpublished report No. 77/WRL2/109 from Life Science Research, Stock, Essex, United Kingdom. Submitted to WHO by Mallinckrodt, Harefield, Uxbridge, Middlesex, United Kingdom.
- Tietz, N. W. ED (1995):** Clinical Guide to Laboratory Tests. 3rd Ed. AACC. Philadelphia, WA Saunders.
- TORBICA, G. ; LJILJANA ,B. ; Dubravka,L. ; Dražen, D. ; Marija , L. ; Ivica, H. and Mario, K. (2013) :** Canine babesiosis treatment with three different medicines. Acta veterinaria 63(2-3):279-290
- Valerie J. Weiba.(2015):** Drug Therapy for Infectious Diseases of the Dog and Cat, John Wiley & Sons ,ISBN: 978-1-118-55734-1.
- (JECFA) Joint FAO/WHO Expert Committee on Food Additives (1998):** WHO FOOD ADDITIVES SERIES 41 Prepared by The 50th meeting of the World Health Organization.
- Young, D.S.(1995):** Effect of Drugs on clinical Lab.Tests,4th Ed, AACC Press.

## المخلص العربي تأثير الأميدوكارب داي- بروبيونات على التطور الجنيني فى الفئران

مجدي عامر - \*جيهان جاد - ريهام الشافعى - رشا الطايش - فايزة عبد المعطى

قسم الأدوية كلية الطب البيطري جامعة المنصورة- \*معهد بحوث صحة الحيوان- الزقازيق

يعتبر عقار الأميدوكارب من أقوى العقاقير القاتلة للطفيليات وخاصة طفيل البابينزيا فى الحيوانات المختلفة. وعلى الرغم من ذلك فان عقار الأميدوكارب يتم إخراجة فى اللبن كما انه يعبر الحاجز المشيمى للأمهات. لذلك اجري هذا البحث لدراسة مدى سمية هذا الدواء على الأجنة وعلى إناث الفئران البيضاء أثناء فترة الحمل . حيث تم دراسة التشوهات الجنينية وفحص الهياكل العظمية والأعضاء الداخلية للأجنة وذلك بعد حقن الأمهات بالجرعة العلاجية فى اليوم السادس واليوم العاشر من الحمل.

وقد أظهرت النتائج أن استخدام الجرعة العلاجية من العقار أدى إلى حدوث بعض التشوهات فى الأعضاء الداخلية كما أدى إلى حدوث تشوهات عظمية فى الأجنة بالإضافة الى حدوث تغيرات فى انزيمات الكبد والكلى للأناث المعالجة أثناء فترة الحمل. لذا ننصح بعدم استخدام هذا العقار فى الحيوانات العشار لتجنب اى تأثيرات ضارة محتملة على الأجنة .