

6-1-2019

Mesenchymal stem cells ameliorate ischemia reperfusion induced acute kidney injury in rat model

Basma Othman

Medical Experimental Research Center, Faculty of Medicine, Mansoura University, Egypt

Esam Mosbah

Department of Surgery, Anesthesiology and Radiology, Faculty of Veterinary Medicine, Mansoura University, Egypt.

Mohamed Sobh

Department of Nephrology & Urology, Faculty of Medicine, Mansoura University, Egypt.

Adel Zaghloul

zagloladel@yahoo.com

Follow this and additional works at: <https://mvmj.researchcommons.org/home>

How to Cite This Article

Othman, Basma; Mosbah, Esam; Sobh, Mohamed; and Zaghloul, Adel (2019) "Mesenchymal stem cells ameliorate ischemia reperfusion induced acute kidney injury in rat model," *Mansoura Veterinary Medical Journal*: Vol. 20: Iss. 2, Article 10.

DOI: <https://doi.org/10.21608/mvmj.2019.22.101>

This Original Article is brought to you for free and open access by Mansoura Veterinary Medical Journal. It has been accepted for inclusion in Mansoura Veterinary Medical Journal by an authorized editor of Mansoura Veterinary Medical Journal.

Mesenchymal stem cells ameliorate ischemia reperfusion induced acute kidney injury in rat model

Basma H.Othman¹, E. Mosbah², M. Sobh³, A. Zaghloul²

¹Medical Experimental Research Center, Faculty of Medicine, Mansoura University, Egypt.

²Department of Surgery, Anesthesiology and Radiology, Faculty of Veterinary Medicine, Mansoura University, Egypt.

³Department of Nephrology & Urology, Faculty of Medicine, Mansoura University, Egypt.

ABSTRACT

Mesenchymal stem cells (MSCs) have generated a great deal of excitement and promise as a potential source of all types of cells for cell-based therapeutic strategies. The present study aimed to evaluate the ameliorative effect of MSCs injected via tail vein and sub-capsular in rats with ischemia reperfusion induced acute kidney injury. A total number of 72 Sprague dawely rats were used in this study and were divided into 3 groups: group (I): Negative control (n=18), group (II): ischemic reperfusion untreated(n=18) and group (III): ischemic reperfusion treated with MSCs (36 rats). Group (III) was divided into two sub-groups: the first subgroup was treated with MSCs injected via tail vein;(n=18) and the second one was treated with MSCs injected subcapsular;(n=18) . six rats from each group and sub groups were euthanized at day1, days3, and day7 from beginning of the experimental study.for histopathological examination and Biochemical analysis was performed for serum creatinine, blood urea nitrogen (BUN), urine creatinine, kidney malondialdehyde (MDA), nitric oxide (NO).additionally to kidney injury lesion scores for kidneys tissue were performed in all experimental groups.Results of this study revealed that MSCs which injected sub-capsular in rats with ischemic reperfused acute renal injury induced ameliorative effects at day 7 through significant decreasing of serum creatinine, BUN, renal MDA, NO, renal fibrosis score and significantly increases creatinine clearance compared to rat sub-group treated with MSCs injected via tail vein.It was concluded that subcapsular injected MSCs in rats with ischemic reperfused ARI induced ameliorative effectcompared to tail vein injected MSCs in rats .

Key words: *Mesenchymal stem cells, Ischemia - reperfusion, Kidney, Rat*

1. INTRODUCTION

Mammalian kidney has multifarious functions, including maintenance of blood pressure, regulation of Ph and other metabolic processes, such as elimination of nitrogenous wastes and release of endocrine factors. Loss of regional or total blood flow to kidney- induced acute kidney injury (AKI) (Klahr& Morrissey, 2002). Renal warm ischemia reperfusion injury in clinical practice is a consequence of either systemic hypo-perfusion with subsequent circulatory resuscitations or local renal hypo-perfusion following renal transplantation (Dobyan et al., 1980) and surgery of aortic aneurysm related to renal artery (Guinee et al., 1993). Renal ischemia is considered an important mechanism that causes damage to tubular cells in acute renal failure (Dobyan, 1985). Stem cells are undifferentiated cells with significant self-renewal capabilities, able to proliferate and establish daughter cell lines for tissue generation (Nangaku, 2004). MSCs are multipotent cells which great interest to both clinicians and researches for their great potential to enhance tissue

engineering, their ease of isolation and manipulability and potential for differentiation into cartilage, bone, fat, muscle, tendon, skin, hematopoietic-supporting stroma and neural tissue (Matsunaga et al., 2005).The bone marrow is the source of MSCs from which many tissues may be obtained (Nakatsuji et al., 1998).

Systemic delivery (intravenous and intra-arterial injections) is the most commonly used route for MSCs administration (Nakatsuji et al., 1998). However, direct local injection (intraparenchymal injection) may increase the retention and survival of administrated MSCs to some extent (Hewitson, 2009). Administration of MSCs through renal artery can increase the retention of donor cells and enables them homogeneous dissemination to the damaged kidney in a more physiological manner (Zahran et al., 2016). Therefore the aim of the present study was to evaluate the ameliorative effect of subcapsular and tail vein injected MSCs in rats with induced ischemia reperfusion acute kidney injury.

2. MATERIALS AND METHODS

Experimental animals

This study was carried on a total number of 72 male Sprague–Dawley rats (body weight 200–250gm) . Rats were bred and housed in standard metallic cages (6 rats per cage) at temperature 20-25°C with an alternating 12 hours light – dark cycle at the animal house of Medical Experimental Research Center (MERC), Faculty of Medicine, Mansoura University. They were acclimatized to the laboratory conditions, fed standard rat chow and water was available ad libitum. The experimental protocol of this work was approved by the Local Ethical Committee, Faculty of Medicine, and Mansoura University.

Mesenchymal stem cells

Were isolated and prepared at cell culture unit of Medical Experimental Research Center (MERC) according to (Mcfarlin et al., 2006), Faculty of Medicine, Mansoura University.

Experimental design

Rats were allocated into 3 groups. Group (I): Negative control ;(n=18). Group (II): ischemic reperfusion I/R surgically induced as the renal pedicles were clamped with atraumatic vascular clamps for 60 minutes and the rats were subjected to right nephrectomy, then the vascular clamps were released to allow reperfusion to the ischemic kidney untreated ;(n=18). Group (III): ischemic reperfusion surgically induced - treated with MSCs ;(n=36). Group (III) was divided into two subgroups as follow: (III.a): ischemic reperfusion surgically induced treated with MSCs injected via tail vein ;(n=18). and (III.b): ischemic reperfusion surgically induced treated with subcapsular injection of MSCs;(n=18). Six rats from each group and sub group were euthanized at day1, day3, and day7 from beginning of experimental study.

Biochemical analysis

Blood samples were collected from heart, serum separated and used for determination of serum creatinine according to (Murray, 1984), and blood urea nitrogen (BUN) were estimated according to (Tietz et al., 1995). Urine samples were used for determination of urinary creatinine according to (Murray, 1984) in order to calculate creatinine clearance and determination of total protein. These parameters were measured using an automated spectrophotometer (Slim Plus, Italy).

Tissue Preparation

For analysis of MDA, NO the frozen kidneys were taken from all experimental rats and tissue homogenates were prepared, according to (Chen et al., 2012), where 0.5 g of

kidney homogenization was performed using a solution formed from 5 mL of 0.1 M potassium phosphate buffer (pH 6.5), centrifuged at 3000 rpm/5 min; then, the supernatant was aspirated, collected into separate Eppendorf tubes and stored at -20°C for further biochemical analysis of renal tissue MDA and NO.

MDA and NO assays in renal tissues

Renal MDA and NO were determined by using enzymatic colorimetric. MDA was determined according to (Satoh, 1978) and NO was determined according to (Grees et al., 1982).

Histopathological examination

Kidneys were perfused in a retrograde fashion through the abdominal aorta using saline 0.9% till complete clearance of the perfusion fluid. Both kidneys in all groups were harvested, cut longitudinally, fixed in 10% neutral buffered formalin and sections were stained with Masson trichrome, for detection of renal fibrosis, (Cohen & Arthur, 1976).

Statistical analysis

All the data obtained from the experiment were expressed as means \pm SEM. Statistical analysis of data was carried out by software SPSS program package version 17 (SPSS, 2004) using the one-way analysis of variance ANOVA followed by Duncan's Range Test (DMRT) for testing the significant differences between variables. Results were considered significant only at the level of ($p \leq 0.05$).

3. RESULTS

Renal function monitoring

Serum creatinine and BUN: Fig. (1&2) showed in ischemic acute renal injury rats, treated with MSCs via sub-capsular injection significantly ($p \leq 0.05$) decreased serum creatinine at day 3 and significantly ($p \leq 0.05$) decreased BUN at day 7 when compared to control negative group and animal treated with MSCs via tail vein .

Creatinine clearance

Ischemic acute renal injury rats that treated with MSCs via sub-capsular injection showed significant ($p \leq 0.05$) increase in creatinine clearance at day 7 compared to control negative group and animal treated with MSCs via tail vein (Fig. (3)).

Renal (MDA) and nitric oxide (NO) assays in kidney tissue extract

According to, Renal MDA & NO levels were significantly ($p \leq 0.05$) decreased in rats treated with sub-capsular MSCs at day 7 when compared to control group and animals treated with MSCs via tail vein injection Fig. (4&5).

Renal fibrosis score

Revealed that renal fibrosis scores were decreased significantly ($p \leq 0.05$) in rats treated with sub-capsular MSCs at day 7 when compared to control group and rats

treated with **MSCs** via tail vein injection Fig. (6).

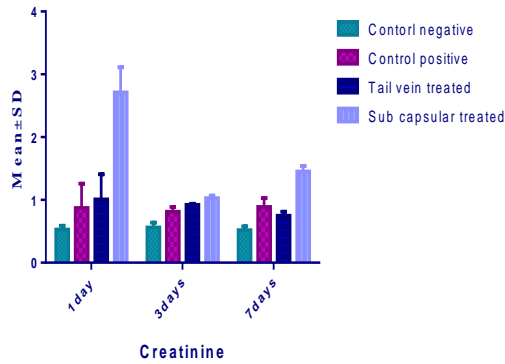


Figure 1. Effect of subcapsular and tail vein MSCs therapy on serum creatinine (mg/dl) in acute renal injury model induced by ischemia-reperfusion in rats.

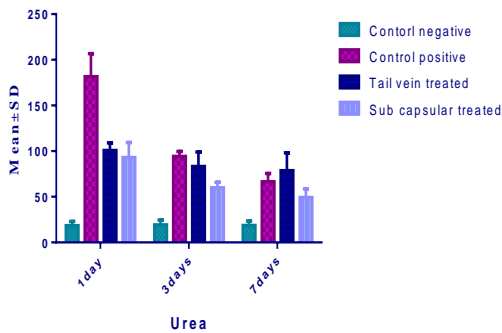


Figure 2. Effect of subcapsular and tail vein MSCs therapy on serum BUN (mg/dl) in acute renal injury model induced by ischemia-reperfusion in rats.

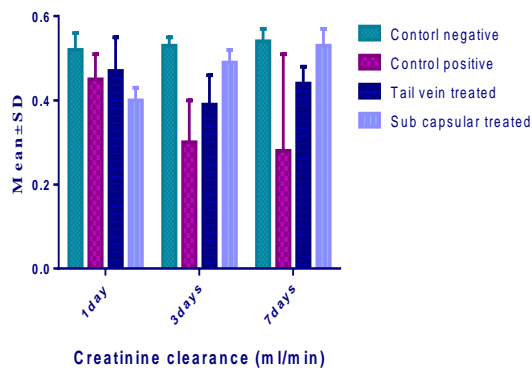


Figure 3. Effect of subcapsular and tail vein MSCs therapy on creatinine clearance (mg/dl) in acute renal injury model induced by ischemia-reperfusion in rats.

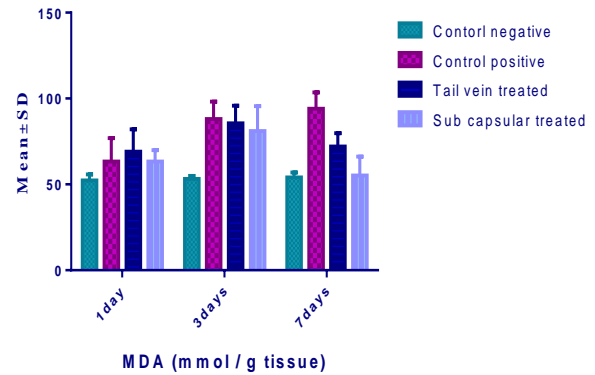


Figure 4. Effect of subcapsular and tail vein MSCs therapy on MDA in tissue extract (nmol /g tissue) acute renal injury model induced by ischemia-reperfusion in rats.

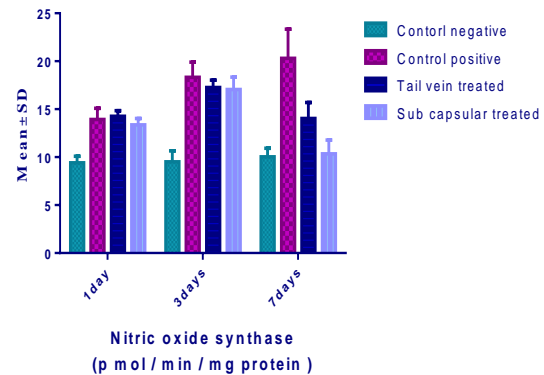


Figure 5. Effect of subcapsular and tail vein MSCs therapy on NO in tissue extract (nmol /g tissue) acute renal injury model induced by ischemia-reperfusion in rats.

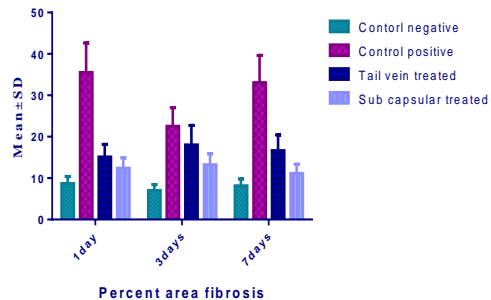


Figure 6. Effect of subcapsular and tail vein MSCs therapy on renal fibrosis in acute renal injury model induced by ischemia-reperfusion in rats.

4. DISCUSSION

Ischemia reperfusion induced acute kidney injury is a common problem among hospitalized patients, mortality rates are high and currently there is no specific medication in use (Waikar et al., 2008). The pathophysiology of I/R-induced AKI is complex and still incompletely understood (Bonventre and Yang, 2011). The damaging effects of renal IR comprise a complex interrelated sequence of events, eventually resulting in both apoptosis and necrosis of the renal cells (Sivarajah et al., 2003).

The emerging field of regenerative medicine is progressing rapidly and supported by a large number of studies demonstrating that stem cells have the capacity to substitute for damaged or lost differentiated cells in various organs and tissues (Zhuo et al., 2001). The anti-inflammatory pattern in MSCs treated animals, indicating the potential of MSCs to modulate (IRI) leading to the earlier regeneration of damaged renal tissue (Chen et al., 2011). Murine rat model was developed to study IRI-induced (AKI) and has many similarities to human IRI-induced AKI was used in all experiments (Kennedy and Erlich, 2008). In rat model the surgical operations can be performed relatively quickly and the duration of ischemia and collection of samples can also be performed at exact time points (Kennedy and Erlich, 2008).

Different experimental studies have provided data using MSCs therapy in various models of I/R-related AKI Soudi et al. (2013). Serum creatinine and S-urea levels are the most widely used clinical markers of kidney function Frank et al. (2012). Creatinine clearance provides a more reliable assessment of renal function Jones et al. (1985). In the present study, the use of sub capsular stem cells was found to be capable of ameliorating renal dysfunction, as demonstrated by improvements of serum creatinine levels, BUN, creatinine clearance. These findings were in agreement with the results of previous study Semedo et al. (2007). In the same trend, Togel et al., (2005) found that MSCs administration either immediately or 24 h after renal ischemia significantly improved renal function.

The sudden drop in blood supply and nutrient delivery leads to a cascade of cellular and tissue events, resulting cytoskeleton disorganization, loss of cell polarity and disfunction of membrane ions transporter. Subsequent reperfusion causes a massive production of reactive oxygen species, which are responsible for oxidation of proteins, lipids and nucleic acid in both epithelial and endothelial cells (Salvadori et al., 2015). Results of this study revealed that, the use of sub capsular stem cells showed the more effective role in amelioration oxidative stress and lipid peroxidation in renal tissues of treated sub-group, as reflected by significant decrease in the levels of malodialdehyde and nitric oxide. NO plays an important role in maintaining normal renal function (Saleh and El-Demerdash, 2005). It was found that the reduction of NO production by the NO synthase inhibitor resulted in exacerbation of I / R-induced AKI (Saad et al., 2002; Saleh and El-Demerdash, 2005).

Bone marrow mesenchymal stem cells might fuse with differentiated cells in various adult organs (Rizvi et al., 2006). Cell fusion could be induced between bone marrow-derived cells and renal tubular cells under conditions of renal damage (Held et al., 2006). The obvious and popular candidate for the Bone marrow cell responsible for ameliorating renal damage is the MSC more than haemopoietic stem cells (Humphreys et al., 2008). MSCs have been shown to protect against (I/R) damage and to accelerate the repair process and tubular regeneration in rodents (Herrera et al., 2004). The results of histopathological examination of renal tissues in rats treated with sub-capsular MSCs confirmed results of previous studies (Semedo et al., 2007) (Togel et al., 2005), by significantly lowering renal fibrosis score.

Conclusions

We concluded that MSCs protect kidney against I/R injury and sub-capsular injection of MSCs in rats with acute kidney injury are more effective than MSCs injected via tail vein. It induces ameliorative effects at day seven through decreasing serum creatinine, BUN, renal oxidative stress and renal fibrosis score and significantly increases creatinine clearance in diseased rat.

5. REFERENCES

- 1- Bonventre, J. V. and Yang, L. (2011): Cellular pathophysiology of ischemic acute kidney injury. *J Clin Invest* 121: 4210-21.
- 2- Chen, p., Powell, B. A., Mortimer, M. and. Ke, P.C. (2012): "Adaptive interactions between zinc oxide nanoparticles and *Chlorella* sp.," *Environmental Science & Technology*. 46(21):12178–12185.
- 3- Chen, Y.T., Sun, C. K. and Lin, Y. C. (2011): Adipose-derived mesenchymal stem cell protects kidneys against ischemia-reperfusion injury through suppressing oxidative stress and inflammatory reaction. *J Transl Med*. 5: 9-51.
- 4- Cohen, M.D. and Arthur, H. (1976): Masson's trichrome stain in the evaluation of renal biopsies. *American J. of clinical pathology*. 65(5): 631-643.
- 5- Dobyan, D. C. (1985): Long-term consequences of cis-platinum-induced renal injury: a structural and functional study. *Anat Rec*. 212:239–245
- 6- Dobyan, D. C., Levi, J., Jacobs, C., Kosek, J and Weiner, M. W. (1980): Mechanism of cis-platinum nephrotoxicity: II. 7- Morphologic observations. *J PharmacolExpTher*. 213:551–556.
- 8- Gress, L. C., Wagner, D. A., Glogowski, J. et al., (1982): Analysis of nitrate, nitrite and 15N nitrate in biological fluids. *Anal.Biochem*. 126:131-138.
- 9- Guinee, D. G, Van Zee, B. and Houghton, D. C. (1985): Clinically silent progressive renal tubulointerstitial disease during cisplatin chemotherapy. *Cancer*. 71:4050–4054.
- 10- Held, P. K., Al-Dhalimy, M. (2006). "In vivo genetic selection of renal proximal tubules." *Mol Ther* 13(1): 49-58.
- 11- Herrera, M. B., Bussolati, B. (2004): "Mesenchymal stem cells contribute to the renal repair of acute tubular epithelial injury." *Int J Mol Med* 14(6): 1035-1041.
- 12 - Humphreys, B. D. Valerius, M. T. (2008). "Intrinsic epithelial cells repair the kidney after injury." *Cell Stem Cell*. 2(3): 284-291.
- 13 - Jones, T. W., Chopra, S., Kaufman, J.S. and Trump, B.F. (1985): Cis-diamminedichloroplatinum-induced acute renal 14 - failure in the rat correlation of structural and functional alteration. *Lab. Invest*. 52: 363-374.
- 15 - Kennedy, S.E. and Erlich, J. H. (2008): Murine renal ischemia- reperfusion injury. *Nephrology*. 13: 390- 396.
- 16- Klahr, S and Morrissey, J. (2002): Obstructive nephropathy and renal fibrosis. *Am J Physiol Renal Physiol*. 283: F861- F75.

- 17- Matsunaga, Y., Kawai, Y., Kohda, Y. and Gemba, M. (2005): Involvement of activation of NADPH oxidase and extracellular signal-regulated kinase (ERK) in renal cell injury induced by zinc. *J Toxicol Sci.* 30:135–144.
- 18 - Murray, R. L. (1984): Creatinine. Kaplan A et al. *Clin Chem the C.V. Mosby Co. St Louis. Toronto. Princeton.* 1261-126.
- 19- Nakatsuji, S., Yamate, J., and Sakuma, S. (1998): Macrophages, myofibroblasts, and extracellular matrix accumulation in interstitial fibrosis of chronic progressive nephropathy in aged rats. *Vet Pathol.* 35: 352–360.
- 20- Nangaku, M. (2004): Mechanisms of tubulointerstitial injury in the kidney final common pathways to end-stage renal failure. *Intern Med.* 2004;43:9–17.
- 21- Rizvi, A. Z., Swain, J. R. et al. (2006): "Bone marrow-derived cells fuse with normal and transformed intestinal stem cells." *Proc Natl Acad Sci U S A.* 103(16): 6321-6325.
- 22- Saad, S. Y. Najjar, T. A., Daba, M. H. and Al-Rikabi, A. C. (2002): Inhibition of nitric oxide synthase aggravates cisplatin-induced nephrotoxicity: effect of 2-amino-4-methylpyridine. *Chemotherapy.* 48: 309–315.
- 23- Saleh, S. and El-Demerdash, E. (2005): Protective effects of L-arginine against cisplatin-induced renal oxidative stress and toxicity: role of nitric oxide. *Basic Clin. Pharmacol. Toxicol.* 97: 91–97.
- 24- Salvadori, M., Rosso, G. and Bertoni, E. (2015): Update on ischemia/reperfusion injury in kidney transplantation: pathogenesis and treatment. *World j. of transplantation.* 5: 52-67.
- 25- Satoh, K. (1978): Serum lipidperoxide in cerebrospinal disorder determined by a new colorimetric method. *Clinical Chemical Acta.* 90: 37- 43.
- 26- Smedo, P., Wang, P.M., Andreucci, M.A., Cenedeze, V.P.A. (2007): Mesenchymal stem cells ameliorate tissue damages triggered by renal ischemia and reperfusion injury. *Transplantation proceeding.* 39(2): 421-423.
- 27- Sivarajah, A., Chatterjee, P. K., Patel, N. S. A, et al. (2003): Agonists of peroxisome-proliferator activated receptor-gamma reduce renal ischemia/reperfusion injury. *The American Journal of Nephrology.* 23(4):267–276.
- 28- Souidi, N., Stolk, M. and Seifert, M. (2013): Ischemia-reperfusion injury: beneficial effect of mesenchymal stromal cells. *Current opinion in organ transplantation.* 18: 34-43.
- 29- SPSS, P. .C (2004): SPSS for windows release 17 SPSS. Inc. USA.
- 30- Tietz, N. W. et al. (1995): Clinical Guide to Laboratory Tests, 3rd ed AAC.
- 31- Togel, F. et al., (2005): Administered mesenchymal stem cells protect against ischemic acute renal failure through differentiation independent mechanisms. *Am. J. Physiol. Renal Physiol.* 289: 31-42.
- 24- Waikar, S. S., Liu, K. D. and Chertow, G.M. (2008). Diagnosis, epidemiology and outcomes of acute kidney injury. *Clin J Am Soc Nephrol* 3: 844-61.
- 25- Zahran, F., Nabil, A., El-Karef, A., El-Sherbiny, I. M. and Sobh, M. (2016): Effect of nano-formulated antioxidant on development of renal fibrosis induced by cisplatin. *J Stem Cell Res Med* 1: doi: 10.15761/JSCRM.1000105.
- 26- Zhuo, W., Liao, L., Xu, T., Wu, W., Yang, S. and Tan, J. (2011): Mesenchymal stem cells ameliorate ischemia-reperfusion-induced renal dysfunction by improving the antioxidant/oxidant balance in the ischemic kidney. *Urologia Internationalis.* 86(2): 191–196.